

Metastatic malignant melanoma to the gallbladder. Case report and review of the literature

G. RIVA¹, M. VILLANOVA¹, A. ECCHER¹, C. LUCHINI¹, F. MOTTA², R. BERNASCONI¹, M. BARBARESCHI³

¹ Department of Diagnostics and Public Health, Section of Pathology, University of Verona, Italy; ² Department of G.F. Ingrassia, Section of Anatomic Pathology, University of Catania; ³ Department of Histopathology, "S. Chiara" Hospital, Trento APSS, Trento, Italy

Key words

Melanoma • Gallbladder • Metastasis

Summary

Solitary metastasis of malignant melanoma (MM) to the gallbladder (GB) is rare and generally originates from skin melanoma. MM is a neoplasm with an often unpredictable course and metastases can potentially affecting all organs. The occurrence of metastasis in the GB is unusual and has only been exceptionally reported in the literature. We describe a case of an 86-year-old man with an isolated MM metastasis located within the GB pre-

senting with symptoms mimicking acute cholecystitis. Anamnestically, he presented a history of malignant melanoma (Clark level III) resected from his left leg 17 years ago. Furthermore we provide a review of the literature with a focus on diagnostic clues to distinguish between primary versus secondary GB MMs and on the best surgical management that should be used.

Case report

An 86-year-old man went to medical observation complaining progressive nausea, vomiting, and increasing right upper quadrant pain. On physical examination, he had a palpable, distended, tender GB. The haematological tests revealed an elevation of her white blood cell count (WBC) to 14 500/mm³ with neutrophilia. Liver function studies were altered: P-AST: 66 U/L; P-ALT: 57 U/L; P-ALP: 503 U/L P-GGT: 833 U/L; P-bil tot: 27,2 µmol/L; P-bil dir: 17,8 µmol/L.

Ultrasound examination of the GB and MR imaging did not demonstrate lithiasis but a polypoid mass without acoustic shadowing. The patient underwent open cholecystectomy the following day. In his past medical history he suffered of malignant melanoma (Clark level III) resected from his left leg 17 years ago. The GB was removed together with the lymph node along the cystic duct. At the sampling of the specimen a dark mass with a polypoid aspect, adherent to the mucosae and projecting itself into the lumen, was found. This lesion measured 1.4 x 2 x 3 cm and presented an homogeneous consistence. At the histological examination, the mucosae was diffusely infiltrated by epithelioid and spindle cells; the epithelium was partially eroded and no junctional activ-

ity was apparent; the cystic duct lymphnode was negative. The neoplastic cells were large, hyperchromatic and had irregular nuclei, as well as a moderate eosinophilic cytoplasm, without melanic pigment. Nucleoli were prominent with numerous pseudoinclusions. Neoplastic cells were strongly reactive to antibodies S-100 protein, MART-1, SOX-10 and vimentin. Only weak positivity for HMB-45 was found (Fig. 1). The postoperative course was uneventful and the patient was discharged on postoperative day 5. The final pathological report was that of metastatic melanoma to the GB. 18F-FDG PET-TC was then performed to exclude others metastatic involvement.

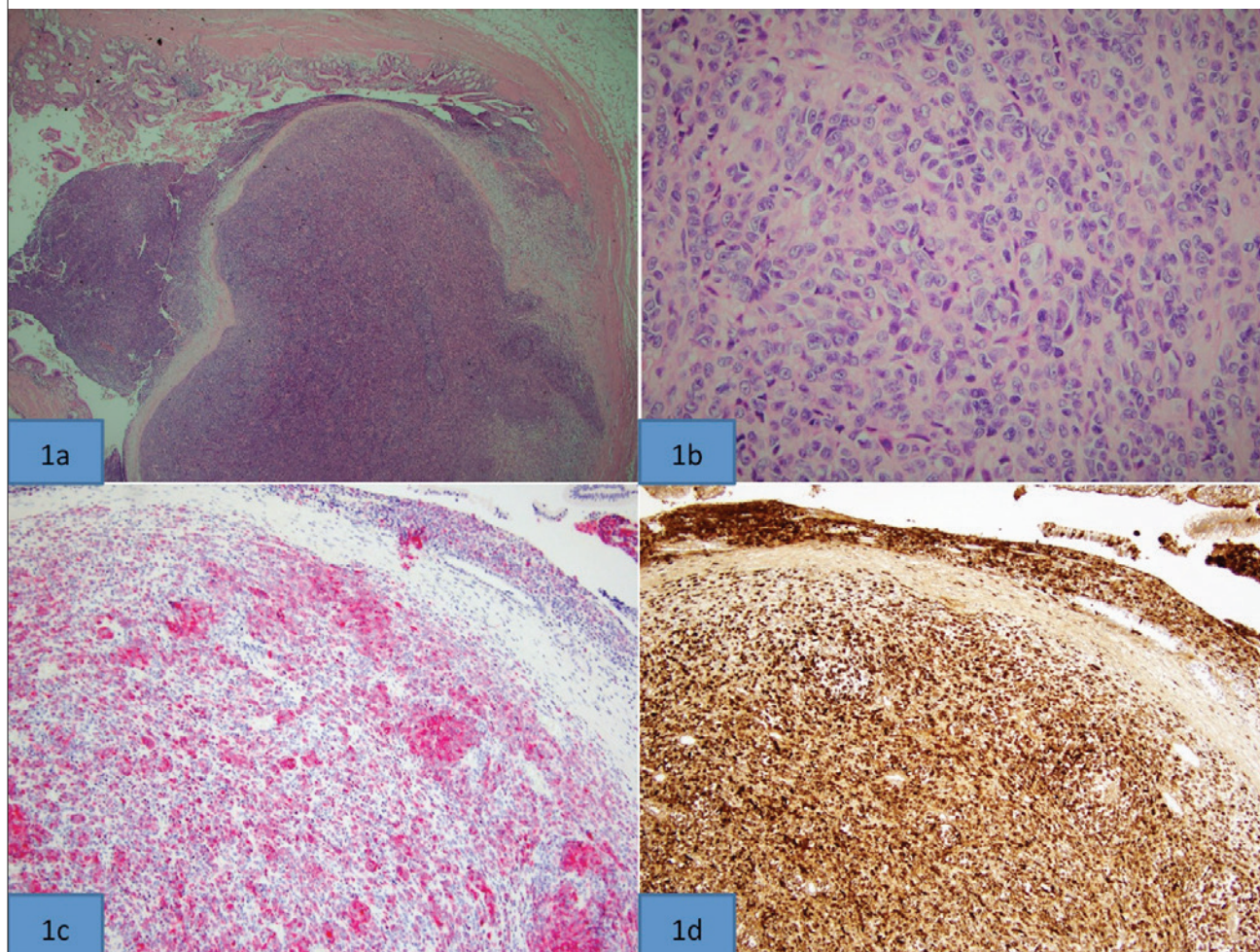
Discussion

MM is the most common neoplasm to metastasize to the gastrointestinal tract. Autopsy reports estimate that up to 15% of these patients also have GB metastases, and MM accounts for up to 60 per cent of metastatic lesions to the GB¹. Only 2 to 4% of patients with melanoma will be diagnosed with gastrointestinal metastasis during the course of their disease. The most common sites of gastrointestinal metastases include the small bowel

Correspondence

G. Riva, A. Stefani Square 1, 37126 Verona, Italy - E-mail: riva23@hotmail.it

Fig. 1. The mucosa was diffusely infiltrated by neoplastic cells 1a (2x E&E); at higher magnification the neoplastic cells showed epithelioid and spindle appearance with irregular nuclei and prominent nucleoli 1b (20x E&E). Immunohistochemical staining revealed strong and diffuse positivity for MART-1 1c and S-100P 1d (5X).



(35-67%), colon (9-15%) and stomach (5-7%), with a median survival of 6-10 months after surgery². The time from the diagnosis of MM to GB metastasis varies between 3 and 13 years³. Just as in our case solitary GB metastasis of MM is rare and generally originates from skin melanoma⁴ and the fact that typically patients do not present until they are symptomatic is further complicating the diagnosis⁵. Primary gastrointestinal melanoma is rare and most gastrointestinal melanomas are metastatic from primary cutaneous lesions. Although MM usually originates from the skin, it can also develop from squamous mucous membranes, uvea, retina, and leptomeninges⁶. To distinguish primary from metastatic melanoma, a junctional component, formed by clustered melanocytes at the mucosa-submucosa junction adjacent to the tumoral mass, must be identified and defined by immunoreactivity. This is the most conclusive histologic evidence for primary melanomas in unusual locations^{7,8}. McFadden comparing primary and metastatic biliary MM found that the two groups displayed remarkable similarity with regard to pathologic findings⁹. According to histogenesis, melanoblasts have not yet been

demonstrated in organs of endodermal origin and GB is an endodermal derivative^{9,10}. On the other hand, non neoplastic melanoblasts resulting from migration of melanin-producing cells from the neural crest to endodermal derivatives during embryologic development explains the presence of melanocytes within their mucosa and supports the possibility of developing primary melanomas at these sites¹¹. Furthermore 70-80% percent had extrabiliary sites of metastasis at some time in the course of their disease, tending to refute the impression of "primary" biliary melanoma. Melanoma in the gallbladder is much more likely to have metastasized from a regressed skin primary than to have arisen *de novo*¹⁰. Criteria proposed by the specific literature for distinguishing primary from secondary GB melanoma include the exclusion of previous primitive melanoma, absence of synchronous involvement of other sites, the unicity of lesion, its polypoid or papillary shape and the presence of a junctional melanocytic component¹². In some cases ultrasound may document metastatic lesions within the GB. However, polypoid lesions in the lumen present a focal thickening of the wall without acoustic shadowing,

due to their lower density in relation with gallstones¹³. Abdominal ultrasound remains the modality of choice in studying GB pathology and has the ability to define metastatic lesions¹. On MR imaging it's possible to appreciate a diffusely thickened wall^{14 15}. An F-18-fluoro-2-deoxyglucose (F-18 FDG) whole-body positron emission tomography/computed tomography (PET/CT) study is often requested with the purpose of staging¹⁵. Most patients with melanoma metastatic to the GB are asymptomatic, and the most common symptom is acute cholecystitis due to cystic duct obstruction³. MM is a neoplasm with an often unpredictable course and metastases potentially affecting all organs. The occurrence of metastasis in the GB is rare and has only been reported in the literature exceptionally¹⁶ but constitutes the most common metastatic lesion involving this organ^{9 17 18}. In the literature there are only few reports on this topic in living patients¹⁷. Isolated metastatic disease to the biliary system is accompanied by obstructive jaundice if the tumor is located in the common bile duct or by upper abdominal pain mimicking symptomatic cholecystolithiasis, but asymptomatic cases were also described¹⁹. In case of metastatic lesions of the gallbladder, treatment options depend on the extension of the disease and on the clinical status of the patient, the only agreement is that surgery is the mainstay treatment²⁰. In patients with melanoma metastatic to the gallbladder, overall survival is determined more by the biology of the disease than treatment. In the presence of symptoms, cholecystectomy is often effective palliation in carefully selected patients²¹. The surgical management seems to be indicated for patients with isolated and resectable GB metastases to avoid symptoms or tumor complications. Laparoscopic approach with gentle manipulation, avoidance of perforation, and use of a retrieval bag for the removal of the gallbladder should be practiced to help minimize the chance of mechanical exfoliation or implantation of malignant cells²². However open surgery has also a concomitant diagnostic purpose because gives the possibility of manual exploration of abdominal cavity, useful particularly to reveal bowel metastatic lesions² and in order to avoid trocar recurrence and perforation of the gallbladder, Christou et al. suggest open cholecystectomy rather than laparoscopic, also to extend the detection of liver or other secondaries unidentified preoperatively^{23 24}. Laparoscopic cholecystectomy without a lymphadenectomy is emerging as the preferred approach for this metastatic deposit²⁵. The "gold-standard" treatment of metastatic melanoma of the gallbladder remains unclear²⁶. The role of systemic adjuvant therapies still remain uncertain for malignant melanoma of the GB as suggested by the most recent NCCN 2013 guidelines. Recently the advent of the immunotherapy drug such as b-ras inhibitor have shown to be more effective and improved survival in phase III trials²⁷. However, because of the limited data available in long standing patients with metastatic disease, further studies are needed.

References

- Nelms JK, Patel JA, Atkinson DP, et al. *Metastatic malignant melanoma of the gallbladder presenting as biliary colic: a case report and review of literature*. Am Surg 2007;73:833-5.
- Marone U, Caracò C, Losito S, et al. *Laparoscopic cholecystectomy for melanoma metastatic to the gallbladder: is it an adequate surgical procedure? Report of a case and review of the literature*. World J Surg Oncol 2007;5:141.
- Dong XD, DeMatos P, Prieto VG, et al. *Melanoma of the gallbladder: a review of cases seen at Duke University Medical Center*. Cancer 1999;85:32-39.
- Furumoto K, Miyauchi Y, Ito D, et al. *Solitary metastatic gallbladder malignant melanoma originated from the nasal cavity: a case report*. Int J Surg Case Rep 2013;4:965-8.
- Khan A, Patel S, Zaccarini DJ, et al. *Metastatic melanoma of the gallbladder in an asymptomatic patient*. Case Rep Gastrointest Med 2017;2017:1767418.
- Bejarano González N, García Moforte N, Darnell Martín A, et al. *Primary malignant melanoma of the common bile duct: a case report and literature review*. Gastroenterol Hepatol 2005;28:382-4.
- Wagner MS, Shoup M, Pickleman J, et al. *Primary malignant melanoma of the common bile duct: a case report and review of the literature*. Arch Pathol Lab Med 2000;124:419-22.
- Deugnier Y, Turlin B, Léhry D, et al. *Malignant melanoma of the hepatic and common bile ducts. A case report and review of the literature*. Arch Pathol Lab Med 1991;115:915-7.
- McFadden PM, Krementz ET, McKinnon WM, et al. *Metastatic melanoma of the gallbladder*. Cancer 1979;44:1802-8.
- Naguib SE, Aterman K. *Presumed primary malignant melanoma of the gallbladder. Report of a case and a review of literature*. Am J Dermatopathol 1984;6Suppl:231-43.
- Dasgupta T, Brasfield R. *Metastatic melanoma. A clinicopathological study*. Cancer 1964;17:1323-39.
- Pitlović V, Latić F, Pitlović H, et al. *Primary malignant melanoma of gallbladder*. Med Glas (Zenica) 2011;8:71-73.
- Holloway BJ, King DM. *Ultrasound diagnosis of metastatic melanoma of the gallbladder*. Br J Radiol 1997;70:1122-5.
- Takayama Y, Asayama Y, Yoshimitsu K, et al. *Metastatic melanoma of the gallbladder*. Comput Med Imaging Graph 2007;31:469-71.
- Özülker T, Özülker F, Cicin İ, et al. *A case of malignant melanoma with cardiac and gallbladder metastases detected by FDG PET-CT*. Clin Nucl Med 2009;34:948-9.
- Swiatoniowski G, Mazur G, Hałoń A, et al. *Malignant melanoma with gall bladder metastasis as a second neoplasm in the course of prostate cancer*. Pathol Oncol Res 2004;10:243-5.
- Uchikov A, Genova S, Dimitrov I, et al. *A case of melanoma metastatic to the gallbladder and the common bile duct with clinical presentation of obstructive jaundice and bilirubinemia*. J Buon 2004;9:317-9.
- Katz SC, Bowne WB, Wolchok JD, et al. *Surgical management of melanoma of the gallbladder: a report of 13 cases and review of the literature*. Am J Surg 2007;193:493-7.
- Seelig MH, Schönleben K. *Laparoscopic cholecystectomy for a metastasis of a malignant melanoma in the gallbladder*. Z Gastroenterol 1997;35:673-5.
- Safioleas M, Agapitos E, Kontzoglou K, et al. *Primary melanoma of the gallbladder: does it exist? Report of a case and review of the literature*. World J Gastroenterol 2006;12:4259-61.
- Katz SC, Bowne WB, Wolchok JD, et al. *Surgical management of melanoma of the gallbladder: a report of 13 cases and review of the literature*. Am J Surg 2007;193:493-7.

- ²² Tuveri M, Tuveri A. *isolated metastatic melanoma to the gallbladder: is laparoscopic cholecystectomy indicated?* Surg Laparosc Endosc Percutan Tech 2007;17:141-4.
- ²³ Simonenko VB, Beliaev LB, Makanin MA, et al. *Primary melanoma of the gallbladder.* Klin Med (Mosk) 2004;82:69-71.
- ²⁴ Christou D, Katodritis N, Decatris MP, et al. *Melanoma of the gallbladder: appropriate surgical management and review of the literature.* Clin Case Reports 2014;2:313-8.
- ²⁵ Khan ZS, Huth J, Kapur P, et al. *Indications and recommended approach for surgical intervention of metastatic disease to the gallbladder.* World J Surg Oncol 2010;8:80.
- ²⁶ Giannini I, Cutrignelli DA, Resta L, et al. *Metastatic melanoma of the gallbladder: report of two cases and a review of the literature.* Clin Exp Med 2016;16:295-300.
- ²⁷ Chapman PB, Hauschild A, Robert C, et al. *Improved survival with vemurafenib in melanoma with BRAF V600E mutation.* N Engl J Med 2011;364:2507-16.