PATHOLOGICA 2023;115:308-317**;**
DOI: 10.32074/1591-951X-920

Original Article

Up-regulation by overexpression of c-MET in fibroblastic foci of usual interstitial pneumonia

Laura Melocchi[1], Giulia Cervi[2], Giuliana Sartori[3], Laura Gandolfi[1], Genny Jocollé[4], Alberto Cavazza[3], Giulio Rossi[1]

[1] Operative Unit of Pathology, Diagnostic Services Area, Fondazione Poliambulanza Hospital Institute, Brescia, Italy; [2] Respiratory Diseases Unit, Carlo Poma Hospital, Azienda Territoriale Socio Sanitaria (ATS) of Mantova, Mantova, Italy; [3] Operative Unit of Pathologic Anatomy, Azienda USL-IRCCS Reggio Emilia, Reggio Emilia, Italy; [4] Operative Unit of Oncology, Azienda USL Valle d'Aosta, Aosta, Italy

Summary

Background. Usual interstitial pneumonia (UIP) is the radiologic and histologic hallmark of idiopathic pulmonary fibrosis (IPF) and the commonest histologic pattern of other progressive fibrosing interstitial lung diseases (e.g., fibrotic hypersensitivity pneumonia). Analogous to lung cancer, activation of epithelial-to-mesenchymal transition (EMT) is one of the main molecular pathways recently identified by transcriptomic studies in IPF. Fibroblastic foci (FF) are considered the active/trigger component of UIP pattern. The proto-oncogene C-MET is a key gene among molecules promoting EMT against which several inhibitors are currently available or promising in ongoing studies on lung cancer.

Methods. Twenty surgical cases of diffuse fibrosing interstitial lung diseases (fILD) with UIP pattern and FF-rich (17 IPF and 3 patients with fibrotic hypersensitivity pneumonia, fHP) were retrospectively selected. FF were manually microdissected and analysed for c-MET gene alterations (FISH amplification and gene hot-spot mutations Sanger sequencing) and tested with a c-MET companion diagnostic antibody (clone SP44 metmab) by immunohistochemistry.

Results. FF are characterized by upregulation of c-MET as shown by overexpression of the protein in 80% of cases, while no gene amplification by FISH or mutations were detected. C-MET upregulation of FF was observed either in IPF and fHP, with a tropism for the epithelial cell component only.

Conclusion. Upregulation of c-MET in FF of ILD with UIP pattern further confirms the key role of the proto-oncogene c-MET in its pathogenesis, possibly representing an interesting and easily-detectable molecular target for selective therapy using specific inhibitors in future clinical trials, similar to lung cancer. It is reasonable to speculate that molecular alterations in FF can also be detected in FF by transbronchial cryobiopsy.

Key words: UIP, IPF, fibroblast foci, c-MET, immunohistochemistry, PCR

Received and accepted: September 14, 2023

Correspondence
Giulio Rossi
Pathology Unit, Diagnostic Services Area, Fondazione Poliambulanza Hospital Institute, via Bissolati 57, 25124 Brescia, Italy
Tel.: 39.030.3508661
E-mail: giurossi68@gmail.com; giulio.rossi@poliambulanza.it

How to cite this article: Melocchi L, Cervi G, Sartori G, et al. Up-regulation by overexpression of c-MET in fibroblastic foci of usual interstitial pneumonia. Pathologica 2023;115:308-317. https://doi.org/10.32074/1591-951X-920

© Copyright by Società Italiana di Anatomia Patologica e Citopatologia Diagnostica, Divisione Italiana della International Academy of Pathology

OPEN ACCESS

This is an open access journal distributed in accordance with the CC-BY-NC-ND (Creative Commons Attribution-NonCommercial-NoDerivatives 4.0 International) license: the work can be used by mentioning the author and the license, but only for non-commercial purposes and only in the original version. For further information: https://creativecommons.org/licenses/by-nc-nd/4.0/deed.en

Introduction

Idiopathic pulmonary fibrosis (IPF) is a chronic, irreversible and progressive, diffuse fibrosing lung disease defined by the radiologic and histologic pattern of usual interstitial pneumonia (UIP), the most common pattern among idiopathic interstitial lung diseases [1,2].

IPF has a lethal outcome with more than 50% of patients dying within 3 years from diagnosis [2-4]. The disease ultimately leads to extensive scarring changes of the pulmonary parenchyma through activation of a complex crossing of several pathways, including extracellular matrix degradation, angiogenesis, lung senescence and Wnt signaling,

non-coding RNA (miRNAs), inflammation and apoptosis among others [3-4]. The dramatic fibrogenic process substituting the alveolar ventilated lung parenchyma is thought to be triggered by chronic alveolar epithelial injuries [2-7], such as smoke, exposure to organic and inorganic toxic agents interplaying in a genetic background increasing the risk of disease, although the cause of IPF remains elusive and its pathogenesis incompletely understood.

Histologically, UIP pattern of fibrosis is defined by a patchwork appearance resulting from abrupt alternating areas of scarred and normal lung, architectural distortion with/without honeycombing change and fibroblastic foci [2,8].

This complex network of mechanisms is variably involved in the pathogenesis of IPF, but also in other diffuse fibrosing lung diseases leading to UIP pattern, mainly fibrotic hypersensitivity pneumonia (fHP) and collagen vascular diseases [2-6]. The impact of molecular studies in the last years is limited by the investigation of bulk tissue comprising various lung compartments and cell types, while novel molecular applications aimed at analyzing single targets and microenvironmental components on human tissue appear to unveil new promising molecular data that could lead to better comprehension of the pathogenetic mechanisms involved in IPF as well as alternative and more effective treatments guided by a targeted approach [7-14].

In this setting, FF are usually seen at the interface between densely fibrotic and relatively normal-appearing lung parenchyma [14,15]. FF are considered the active component and progressing front of UIP pattern finally leading to "end-stage" fibrotic destruction of the lung parenchyma architecture and are thought to be more likely derived from the transformation of alveolar epithelial cells covering the FF through epithelial-to-mesenchymal transition (EMT) phenomenon. EMT is due to the loss of epithelial cell-cell adhesion molecules (e.g., E-cadherin) and concomitant gain of mesenchymal markers (e.g., N-cadherin, alpha-smooth muscle actin) [7,10,11-14].

The well-established role of EMT in the pathogenesis of IPF is supported by the expression of driving transcription factors, such as SNAIL1, SNAIL2 (SLUG), TWIST1, ZEB1, ZEB2 (SIP1), PRRX1 and Goosecoid repressing the molecules of cell-cell adhesion through the activation of signaling pathways that can induce EMT, such as transforming growth factor-beta (TGF-β) [12-14].

The up-regulation of epithelial–mesenchymal transition (EMT) in IPF is further supported by Chilosi et al. [13] who studied the immunohistochemical and immunofluorescent expression of ZEB1, Tubβ3, and β-catenin in all tissue samples from 34 idiopathic pulmonary fibrosis cases that were concurrently expressed in fibroblastic foci, damaged epithelial cells overlying active fibrosis and in pericytes within neo-angiogenesis areas. These results were also confirmed by immunofluorescence assay, indirectly supporting miR-200 deregulation and EMT activation in IPF. The abnormal expression and localization of these proteins in bronchiolar fibro-proliferative lesions is unique for idiopathic pulmonary fibrosis, and might represent a disease-specific marker in challenging lung biopsies.

Again, according to Yamaguchi et al. [14], FF are more likely derived from the epithelial-to-mesenchymal transitioned alveolar epithelia located over them. On the basis of these findings, inhibition of transforming growth factor-β signaling, which can suppress EMT of the alveolar epithelial cells in vitro, is a potential strategy for treating IPF.

Among molecules involved in EMT, deeply investigated in various neoplasms, MET acts as a receptor tyrosine kinase (RTK) and is part of a larger family of growth factor receptors [15-19].

Hepatocyte growth factor (HGF), the ligand of MET, is a member of the plasminogen-related growth factor family that promotes apoptosis of myofibroblast and inhibition of epithelial-to-mesenchymal cell transition (EMT). HGF binding to MET results in receptor homodimerization and phosphorylation of tyrosine residues located in the kinase domain. This causes activation of the mitogen-activated protein kinase (MAPK) cascades, leading MAPK translocation to the nucleus thus activating transcription factors responsible for regulating a large number of genes resulting in cell proliferation, cell motility, cell cycle progression, invasion and transformation [15-19]. Thus, HGF acts as an anti-fibrogenic molecule, but its receptor MET is considered to have a key role in promoting EMT transition both in pulmonary fibrosis and lung cancerogenesis [16,18].

Vukmirovic et al. [19] recently demonstrated a significant increase of c-MET mRNA in a study of large scale genome transcript profiling using RNA sequencing (RNA-Seq) applied to archived formalin-fixed paraffin-embedded (FFPE) IPF tissues. The authors compared 7 cases of IPF with 5 control lung tissue, performing a 50-base paired-end sequencing on Illumina 2000 Hiseq. In the study, 4,131 genes were differentially expressed between IPF and controls (1,920 increased and 2,211 decreased). Pathway enrichment analysis performed using MetaCore confirmed numerous IPF relevant genes including TGF-β WNT, and those involved in extracellular remodelling

and regulation of EMT transition. The study notably demonstrates that sequencing of RNA obtained from archived FFPE lung tissues is feasible, since results obtained from FFPE tissue were highly comparable to fresh frozen tissues.
The ability to perform RNA-Seq on archived FFPE IPF tissues greatly enhances the availability of tissue biopsies for molecular investigations in IPF.
Since FF indicate the site of starting of the disease and represents the pathognomonic histologic modification in the pathogenesis of the pulmonary fibrotic disease with UIP pattern [7,10,11], some researchers have designed studies to specifically microdissect FF and then analyze tissue by gene expression profiling.
In particular, Guillotin et al. [7] first performed a transcriptomic analysis in FF isolated from lung tissue of IPF by laser capture microdissection with identification of clusters of genes associated with cell cycle, inflammation/differentiation, translation and cytoskeleton/cell adhesion. The authors showed that transforming growth factor β1 (TGF-β1), RhoA kinase and the TSC2/RHEB axis formed major signalling targetable clusters associated with collagen gene expression in lung fibrosis and other fibrotic conditions including cancer-associated fibroblasts. While microdissected FF in the study by Guillotin and colleagues included only the mesenchymal myofibroblastic proliferation without the epithelial component, in a subsequent study Kamp et al. [10] microdissected and analyzed the entire sandwich (mesenchymal and epithelial components) of FF in IPF (6 cases) and chronic fibrotic sarcoidosis (6 cases) by gene expression signature evidencing upregulation of several genes, including c-MET.
Similarly, Calabrese et al. [11] used the same approach in a study on microdissected FF (entire sandwich) from 12 IPF (10 lung transplantations and 2 diagnostic VATS). The authors found 23 up-regulated genes compared with normal lung from spontaneous pneumothorax, mainly related to epithelial cell adhesion (high molecular weight cytokeratins, desmocollin-3, CEACAM 5-7), cell migration/EMT (MET), senescence, programmed cell death (Serpine1) and secretory mucin proteins (MUC5AC, MUC5B).
Since FF share several pathogenetic mechanisms with lung cancer, including EMT upregulation, and the proto-oncogene c-MET is a druggable receptor tyrosine kinase against which promising inhibitors are still available and ongoing, the aims of this study were the following: i) to demonstrate the feasibility of microdissection of FF using a manual, light microscope-guided approach, enabling; ii) extractive molecular analysis of DNA alterations focused on investigation of one of the main genes involved in EMT pathway, namely the proto-oncogene c-MET (FISH amplification and gene mutations in the most important hot spots) in FF; iii) the product of c-MET gene was analyzed in FF by immunohistochemical expression using a companion diagnostics test (CDx anti-total met clone SP44 metmab, Ventana/Roche) performed for lung cancer [20].

Materials and methods

Twenty cases of diffuse fibrosing interstitial lung disease with UIP pattern (17 IPF, 3 fibrotic HP) were selected for the study. The cases were from routine practice and consultation archive of one of the authors (GR) diagnosed between January 2013 and October 2017. All patients had a definitive diagnosis established through multidisciplinary review of clinical, radiological, and pathological data, according to the last criteria of international Guidelines [1,2].
The study was approved by local Ethical Committee (code RE14790). All patients ultimately died and the patient's consensus was obtained from the Privacy Authority. All information regarding human material was anonymously managed through numerical code identification. All samples were handled in compliance with the Helsinki Declaration (http://www.wma.net/en/30publications/10policies/b3/).
The UIP pattern was histologically confirmed on lung tissue obtained from surgical biopsy using a video-assisted thoracoscopic approach. All lung specimens were formalin-fixed for at least 14 and no more than 24 hours, then entirely sampled after removal of the metallic staples at the resection margins, and slices obtained with perpendicular sections on the long axis of the specimen were then paraffin-embedded. From each paraffin block, 4-µm thick sections were obtained and routinely stained with hematoxylin-eosin for examination at light microscopy. For in situ (immunohistochemistry, FISH) and extractive molecular analysis, only paraffin-embedded blocks containing at least 10 FF x slide were selected.
With FF we considered the scattered, tiny structures composed of a micronodular aggregate of fibroblasts/myofibroblasts lined by metaplastic epithelial cells (Fig. 1) (so-called epithelial/myofibroblastic sandwiches). The availability of a sufficient number of fibroblastic foci was then a prerequisite to enter in the study, since this specific finding was the target of molecular studies.

Immunohistochemistry (IHC)

The IHC evaluations were performed using the rabbit

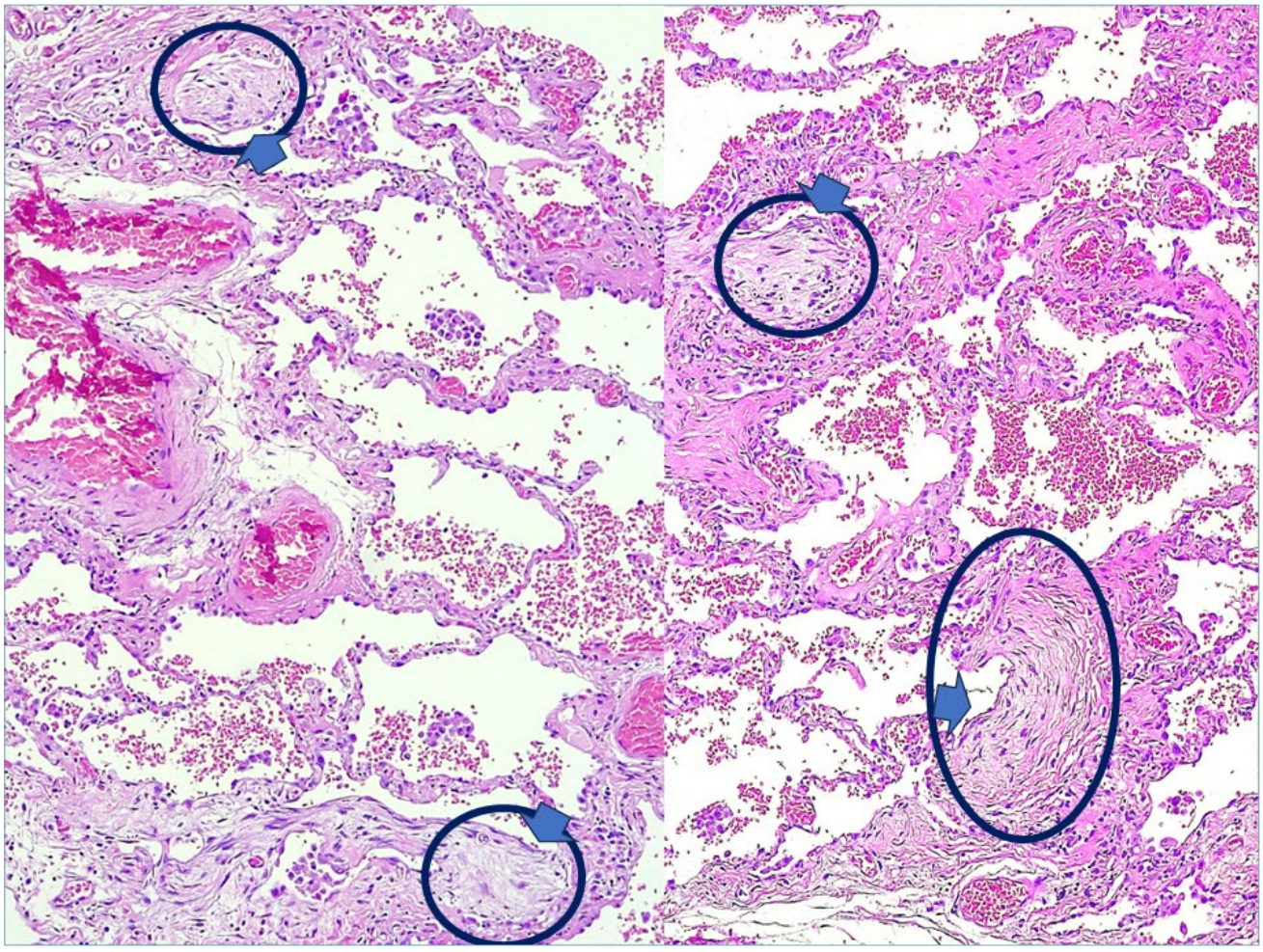

Figure 1. A case of IPF with several fibroblastic foci (blue circles) characterized by a superficial layer of epithelial cells (blue arrows) covering the proliferation of fibro/myofibroblastic mesenchymal component (hematoxylin-eosin, magnification x 100).

monoclonal primary antibody anti-total c-MET (clone SP44, Ventana Medical Systems, Roche, prediluted) revealed using an UltraView Universal DAB Detection Kit (Ventana Medical Systems, Tucson, AZ). The IHC staining procedure was carried out according to the manufacturer's instructions using the ULTRA automated immunostainer (Ventana BenchMark Ultra). The IHC staining was evaluated by 2 pathologists according to modified MetMab criteria [17,20].Accordingly, FF were considered as MET positive when strong MET membranous and/or cytoplasmic staining (2+or 3+) was noted in more than 50% of epithelial and\or mesenchymal cells. Finally, a case was rated as positive or MET overexpressed when at at least 50% of examined FF in immunotested slides were positive.

FISH analysis

FISH evaluation of MET was performed using unstined FFPE tumor tissue sections, as elsewhere described [21]. FISH analysis was performed using the ZytoLight SPEC MET/CEN 7 Dual Color Probe (PL46) (Bio-Optica, Milan, Italy), according to the manufacturer's instructions. It should be noted that a minimum of 50 non-overlapping epithelial and/or myofibroblastic cells comprised in the FF with hybridization signals were analyzed in each sample under a fluorescence microscope (BX51, Olympus, Tokyo, Japan).
MET amplification was recorded by estimating the ratio between the number of MET copies and the copies of the chromosome 7 centromere (CEP7) according to Ding et al. [21]. Mean cMET/CEP7 ratio was calcu-

lated for each probe by scoring the number of c-MET and CEP7 each nucleus independently. MET copy number ≥ 5 and/or MET:CEP7 signal ratio ≥ 2 were considered as amplification. In contrast, MET:CEP7 ratio of < 2 was classified as non-amplified MET. While patients with MET copy numbers of ≥ 5 but a ratio of < 2 were classified as MET gain, both MET and CEP7 copy numbers of ≥ 3 but < 5 were classified as MET polysomy [21].

Molecular analysis

Five-µm thick sections obtained from a representative paraffin-embedded block were deparaffinized using xylene, and tumor DNA was extracted manual microdissection method under the guide of a light-microscope (Leica DM750 with incorporated ICC50W camera, Buccinasco/Milan, Italy). Manual microdissection of fibroblast foci with overlying alveolar pneumocytes was at 100X magnification (objective X10) on hematoxylin-eosin-stained slides without coverslip using a sterile needle (27 G, Agani Needle, Terumo Europe, Hamburg, Germany). At least 50 fibroblast foci per case were dissected and placed into a sterile Eppendorf tube (Fig. 2). Microdissected cells were then processed as previously described [22]. The forward and reverse oligonucleotide primers used to amplify c-MET exons are listed in Table I.

Statistical analysis

Statistical calculations with comparison of categorical variables were performed using the chi-square statistic with the Fisher exact test P values.

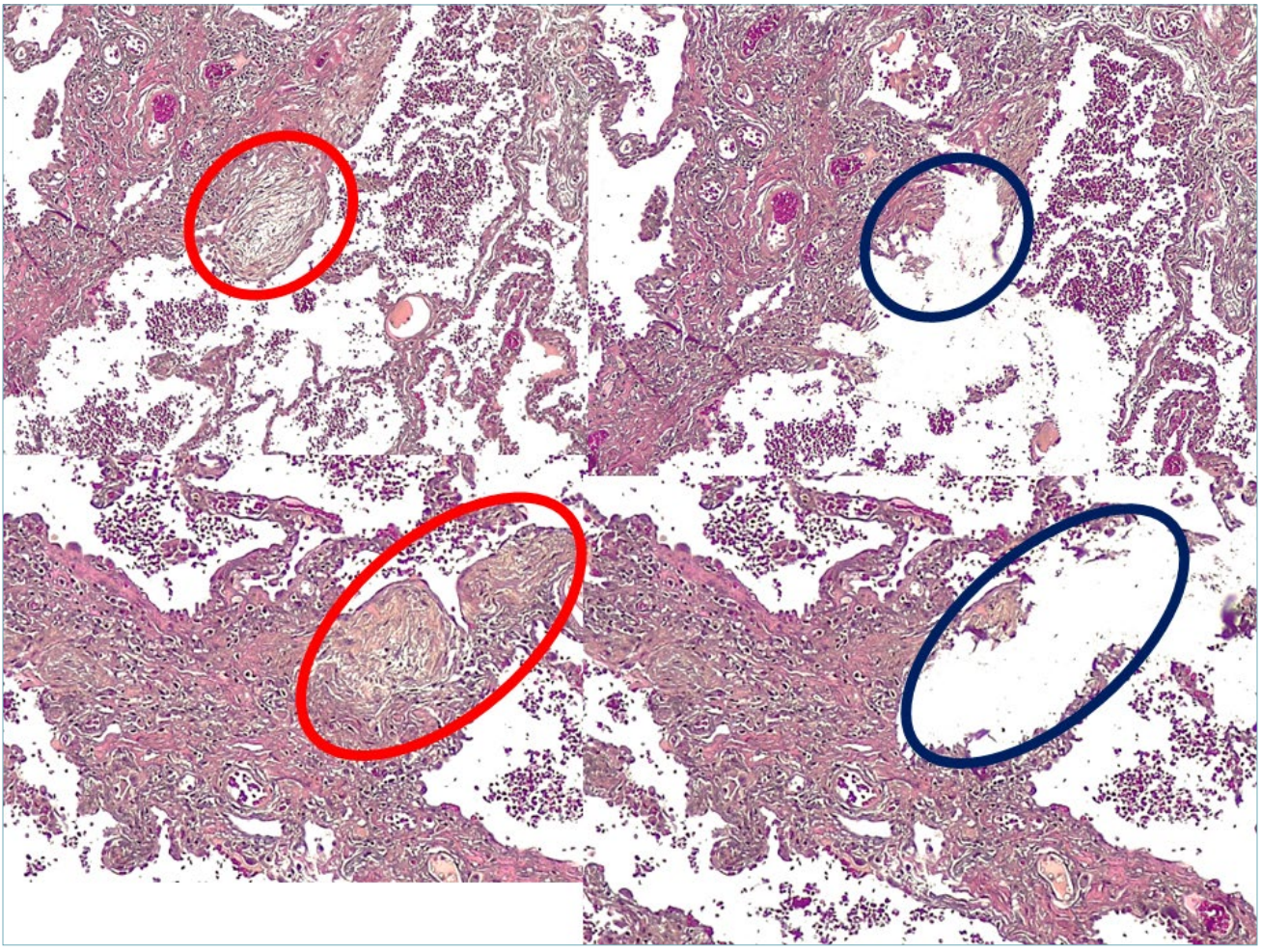

Figure 2. A case of IPF with several fibroblastic foci before (orange circles) and after (blue circles) microdissection using an hematoxylin-eosin-stained slide without coverslide (hematoxylin-eosin, magnification x 100). Microdissection included all epithelial and mesenchymal components (sandwich) of fibroblastic foci.

Table I. Oligonucleotide primers used in the study.

Primer name	Primer sequence	A.T.	Product size (bp)
Exon 14 c-MET	Forward 5'-TTC TGG GCA CGT GGT CAA AGT-3' Reverse 5'-AAT GTC ACA ACC CAC TGA GGT-3'	58°C	282 bp
Exon 17 c-MET	Forward 5'-GTA TTC ACT GTT CCA TAA TGA AGT-3' Reverse 5'-GAT GGC TGG CTT ACA GCT AGT-3'	55°C	287 bp
Exon 18 c-MET	Forward 5'-AAC AGT AGA TGC TTA GTT TAT GCT-3' Reverse 5'-AAC AGA TTC CTC CTT GTC ACT T-3'	55°C	215 bp
Exon 19 c-MET	Forward 5'-TTC TAT TTC AGC CAC GGG TAA T-3' Reverse 5'-ATG AAA GTA AAA GAG GAG AAA CTC-3'	55°C	253 bp

A.T., annealing temperature.

Results

The case series consisted of 20 patients with diffuse fibrosing interstitial lung disease with UIP pattern at histology, classified as IPF (n = 17) and fibrotic hypersensitivity pneumonia (fHP, n = 3) after multidisciplinary discussion, in agreement with the most recent international guidelines [1,2].

There were 15 males (75%) and the median age was 66 years (range, 54-80 years).

At the time of diagnosis, 45% of patients were stable, while 11 were in progression.

The main clinicopathologic data of the series is summarized in Table II.

No significant differences were observed when the variables were matched by statistical analysis.

Immuno-molecular determinations

Direct Sanger sequencing of microdissected FF did not show mutations in the c-MET exons investigated (Fig. 3).

FISH analysis performed for c-MET gene amplification did not reveal increased copies of the gene (Fig. 4).

Immunohistochemical expression of MET protein using the total MET monoclonal cDx SP44 (metmab) evidenced overexpression in 80% of the cases, 82.3% (14 of 17) in IPF and 66.6% (2 of 3) in fHP.

Of note, MET overexpression is noted in the epithelial cells of FF, but not in the mesenchymal component (Fig. 5).

No significant expression was identified in any other tissue compartment of the lung.

No significant differences were observed when the variables were matched by statistical analysis.

Discussion

Fibroblastic foci (FF) are one of the main histologic hallmarks of ILD with UIP pattern, either in IPF and

Table II. Summary of the main clinicopathologic characteristics of patients included in the study.

Characteristics	Cases (n = 20) N.	%	IPF (n = 17)	fHP (n = 3)
Age	Median, 66 years (range: 54-80 years)		71	65
Gender				
• Male	15	75	13	1
• Female	5	25	2	2
Smoking habit				
• Current/former	16	69	15	1
• Never	4	31	2	2
Disease				
• IPF	17	85		
• Fibrotic HP	3	15		
HRCT				
• Probable	12	60	11	1
• Possible	6	30	5	1
• Indeterminate	2	10	1	1
BAL				
• Neutrophilic alveolitis	11	55	11	-
• Lymphocytic alveolitis	2	10	-	2
• Not performed	7	35	6	1
Clinical status at diagnosis				
• Stable	9	45	4	5
• Progression	11	55	10	1
FVC				
• FVC > 80%	13	65	11	2
• FVC < 80%	7	35	6	1
DLCO				
• DLCO > 50%	12	60	11	1
• DLCO < 50%	6	30	4	2
• No DLCO	2	10	2	-
Therapy				
• Steroid	9	53.8	6	3
• Steroid/NAC/ immunosoppressore	8 3	38.5 7.7	8 3	- -
• Nintedanib				
c-MET molecular analysis				
• Wid-type setup.	13	100	-	-
• Mutated	0	0		
FISH				
• Amplification	0	0		
• Normal setup	20	100		
c-MET overexpression				
• Negative	4	20	3	1
• Positive	16	80	14	2

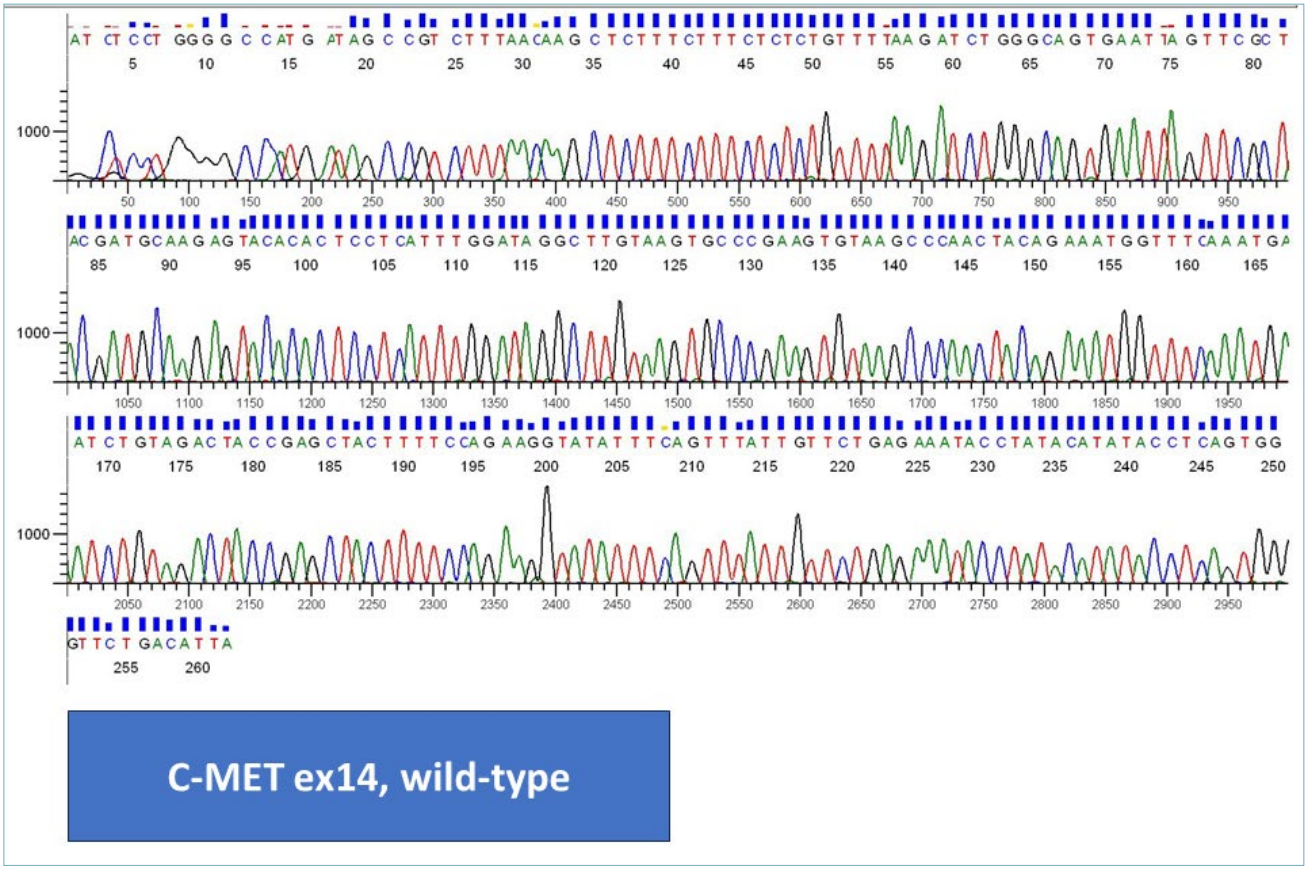

Figure 3. Electropherogram of direct Sanger showing of the c-MET exon 14 evidencing a wild type gene.

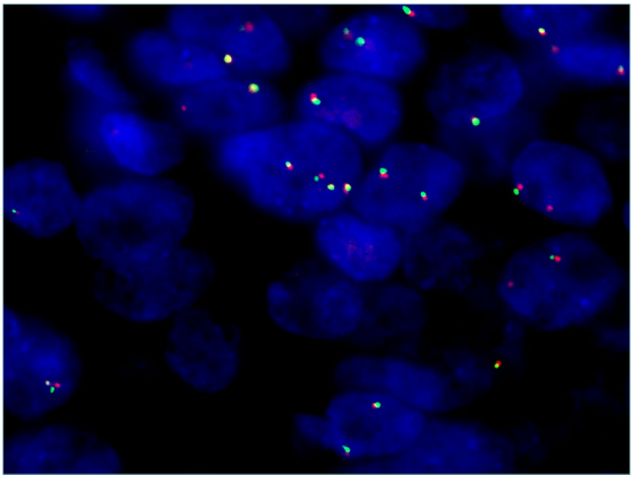

Figure 4. FISH analysis using a MET/CEN7 dual color probe in epithelial and mesenchymal cells of fibroblastic foci showed a regular < 2 MET/CEN7 ratio.

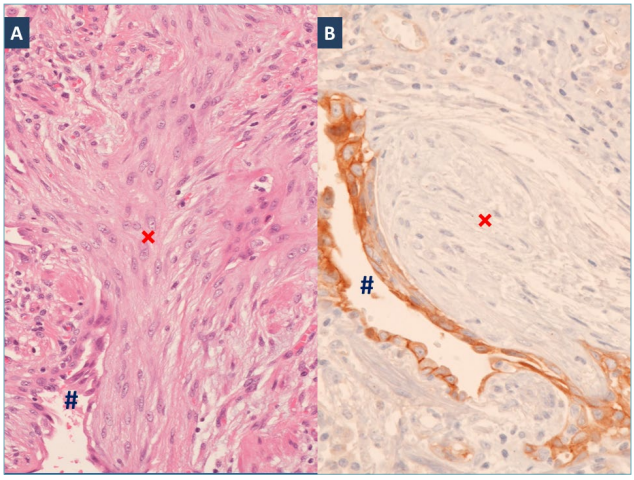

Figure 5. A case of IPF with fibroblastic foci (A, hematoxylin-eosin staining, magnification x 200) showing overexpression of c-MET (clone SP44) in the epithelial component (indicated by blue hashtags) but not in mesenchymal part (red crosstrees) of fibroblastic foci (immunohistochemistry, magnification x 200) or other lung structures.

secondary UIP, such as fibrotic hypersensitivity pneumonia [2-4,6,14]. FF are considered the active/trigger component of UIP, possibly resulting from chronic injuries to the alveolar epithelial cells leading to mesenchymal activation with localized proliferation of fibroblast/myofibroblasts [2-4,6,7,10,11,14]. The numerosity of FF in UIP is directly correlated to disease progression and poor outcome [2-4]. FF interestingly represent a tissutal compartment of UIP characterized by the activation of epithelial-to mesenchymal transition (EMT), as recently demonstrated in various studies [7,10,11,13,14]. Chilosi et al [13]. provided robust evidence that Tubβ3, ZEB1 and β-catenin, target proteins of the miR-200-family, are abnormally expressed at sites of damage and repair in IPF, with specific localization in FF and epithelial cells of honeycombing changes. As already suggested, ZEB1 is a crucial activator of epithelial to mesenchymal transition, and its expression in epithelial cells is triggered by different signaling pathways and transcription factors, including Wnt-β catenin, TGFβ, and Twist, all molecules upregulated in IPF [3,4,14].

Of note, aberrant up-regulation of the proto-oncogene c-MET is emerged in several transcriptomic studies on mRNA in IPF [7,8,10,11,19]. c-MET is considered an important actionable target in many solid tumors [18,20-23]; therefore, biomarker discovery becomes essential in order to guide clinical intervention and patient stratification with the aim of moving towards personalized medicine.

MET, a high affinity tyrosine kinase receptor for hepatocyte growth factor (HGF, also known as scatter factor) is a disulfide-linked heterodimer made of 45 kDa α- and 145 kDa β-subunits (1,2). The α-subunit and the amino-terminal region of the β-subunit form the extracellular domain. The remainder of the β-chain spans the plasma membrane and contains a cytoplasmic region with tyrosine kinase activity. Interaction of MET with HGF results in autophosphorylation at multiple tyrosines, which recruits several downstream signaling components, including Gab1, c-Cbl, and PI3 kinase [15-18,23]. These fundamental events are important for all of the biological functions involving MET kinase activity. Phosphorylation at Tyr1234/1235 in the Met kinase domain is critical for kinase activation [15-18], whereas phosphorylation at Tyr1349 in the Met cytoplasmic domain provides a direct binding site for Gab1. Research studies have shown that altered MET levels and/or tyrosine kinase activities are found in several types of tumors, including renal, colon, and breast cancer [16-18,23]. Thus, investigators concluded that Met is an attractive potential cancer therapeutic and diagnostic target [23].

Immunohistochemical evaluation demonstrated that hyperplastic alveolar type II epithelial cells, as well as alveolar macrophages, were strongly stained with anti-HGF antibody in tissues of patients with IPF. The concentration of HGF in bronchoalveolar lavage fluid (BALF) was significantly higher than in normal controls (0.23 +/- 0.09 pg/microg) in patients with IPF (0.77 +/- 0.88 pg of HGF/microg of albumin, $P < 0.001$), lung fibrosis associated with rheumatoid arthritis (0.50 +/- 0.64 pg/microg, $P < 0.01$), and sarcoidosis (0.41 +/- 0.61 pg/microg, $P < 0.05$) [15-18]. In situ hybridization revealed mRNA for HGF in alveolar macrophages (especially small monocyte-like macrophages). These results indicate that the increase in HGF in peripheral air spaces is due to augmented HGF production by alveolar epithelial cells and alveolar macrophages. HGF, through a paracrine mechanism, may play an important role in the repair and healing of the inflammatory lung damage in pulmonary fibrosis [15,18].

Therefore, there is a consistent body of evidence to state that EMT pathway involving HGF/c-MET is disrupted in IPF. Although preliminary, the current data further support the role of c-MET as an interesting molecular target in pulmonary fibrosis with UIP pattern.

The original study design here proposed also suggests that clinical trials in IPF may replicate those in lung cancer evidencing druggable molecular biomarkers.

It is of note that promising results have been observed in phase I and II studies using telisotuzumab vedotin, an antibody-drug coniugate targeting c-MET, in monotherapy in advanced non-small cell lung cancer (NSCLC) characterized by overexpression of c-MET using the same metmab companion diagnostic immunohistochemistry clone SP44 with the scoring system adopted for FF here presented [20]. Camidge et al. [24]. demonstrated that Teliso Vedotin monotherapy was well-tolerated and showed antitumor activity in c-MET positive NSCLC.

Since cryobiopsy is the emerging diagnostic interventional procedure to obtain tissue in IPF, and hence FF are easily recognizable in these samples, selective dissection of FF for DNA/RNA extraction seems entirely feasible in lung tissue from cryobiopsy [25].

Finally, the current and previous similar molecular studies obtaining good-quality DNA/RNA from patients with IPF and other ILD with UIP pattern archived in Pathology Units, should convince researchers to implement molecular studies with different methodologies, also permitting isolation of tissue from specific lung compartments of UIP [7,8,10,11,19]. A summary of the main findings and study details of all published works

Table III. Summary of the main molecular findings from studies microdissecting fibroblastic foci in interstitial lung disease with UIP pattern.

Reference	Case series	Type of dissection	Analyzed material	Main results
Guillottin [7] 2021	FFPE lung tissue with IPF	Laser capture microdissection of myofibroblastic component of FF	mRNA	Prominent clusters of genes associated with cell cycle, inflammation/differentiation, translation and cytoskeleton/cell adhesion
Kamp [10] 2021	FFPE tissue from IPF (6 cases) and fibrotic sarcoid (6 cases)	Laser capture microdissection of entire FF sandwiches	mRNA	Up-regulation of several genes, including c-MET. Different expression of CAT1 and SMURF1 between IPF and sarcoid
Calabrese [11] 2022		Laser capture microdissection	mRNA	23 up-regulated genes when compared with normal lung from spontaneous pneumothorax, mainly related to epithelial cell adhesion (high molecular weight cytokeratins, desmocollin-3, CEACAM 5-7), cell migration/EMT (MET), /senescence/ programmed cell death (Serpine1) and secretory mucin proteins (MUC5AC, MUC5B)
Current series	FFPE lung tissue from IPF (\7 IPF) and fHP (3 cases)	Manual microdissection under light microscope of entire FF sandwiches	DNA (amplification and hot spots mutations of the proto-oncogene c-MET	No genetic alterations of the proto-oncogene c-MET Up-regulation by protein overexpression

Abbreviations: FFPE, formalin-fixed paraffin-embedded; IPF, Idiopathic pulmonary fibrosis; fHP, fibrotic hypersensitivity pneumonia; FF, fibroblastic foci; mRNA, messanger ribonucleic acid; DNA, deoxyribonucleic acid, c-MET, MET protooncogene hepatocyte growth factor receptor.

microdissecting FF in IPF or other ILD with UIP pattern are reported in Table III.

Of course, this study has several limitations, as follows: a. this is a retrospective observational analysis including selected cases of ILD with UIP pattern comprising several FF, then excluding similar cases characterized by a limited quantity of FF; b. manual microdissection cannot permit an adequate separation (if of some help) of the epithelial cells from fibroblast/myofibroblast component of FF; c. molecular analysis was focused on a limited number of exons of c-MET gene (although including hotspots); d. all cases were from surgical specimens, while there is a worldwide tendency to limit surgical biopsy procedures in favor of less invasive bronchoscopy approach with transbronchial cryobiopsy.

Conclusions

Upregulation of c-MET in FF of ILD with UIP pattern further confirms the key role of the proto-oncogene c-MET in its, possibly representing an interesting easily-detectable molecular target for selective therapy using specific inhibitors in future clinical trials, similarly to lung cancer. It is reasonable to speculate that molecular alterations in FF can also be detected in FF from transbronchial cryobiopsy.

Conflicts of interest

The authors declared no conflicts of interest with respect to the authorship and/or publication of this article. All the material (text, tables and images) used for the current research article is entirely original and never published elsewhere.

Funding

This research did not receive any specific grant from funding agencies in the public, commercial, or not-to-profit sectors

Authors' contributions

GR, LM, AC conceived and supervised the study. GS, GJ and LG conceived and conducted all molecular determinations and GC performed the associated analyses and assisted in characterizing the histological stains and identification of clinical morphologies associated with interstititial lung diseases. LM, GR, GC, AC and wrote the manuscript and all authors revised and approved the final version.

Ethical consideration

The study was approved by Ethical Committee of Azienda SMN Reggio Emilia (code RE14790). All patients ultimately died and the patient's consensus was obtained from the Privacy Authority. All information regarding the human material was anonymously

managed through numerical codes identification. All samples were handled in compliance with the Helsinki Declaration (http://www.wma.net/en/30publications/10policies/b3/).

References

1 Travis WD, Costabel U, Hansell DM, et al. An official American Thoracic Society/European Respiratory Society statement: Update of the international multidisciplinary classification of the idiopathic interstitial pneumonias. Am J Respir Crit Care Med 2013;188:733-748. https://doi.org/10.1164/rccm.201308-1483ST

2 Raghu G, Remy-Jardin M, Richeldi L, et al. Idiopathic Pulmonary Fibrosis (an Update) and Progressive Pulmonary Fibrosis in Adults: An Official ATS/ERS/JRS/ALAT Clinical Practice Guideline. Am J Respir Crit Care Med 2022;205:e18-e47. https://doi.org/10.1164/rccm.202202-0399ST

3 Spagnolo P, Kropski JA, Jones MG, et al. Idiopathic pulmonary fibrosis: disease mechanisms and drug development. Pharmacol Ther 2021;222:107798. https://doi.org/10.1016/j.pharmthera.2020.107798

4 Wolters PJ, Collard HR, Jones KD. Pathogenesis of idiopathic pulmonary fibrosis. Annu Rev Pathol Mech Dis 2014;9:157-179. https://doi.org/10.1146/annurev-pathol-012513-104706

5 Raghu G, Remy-Jardin M, Ryerson CJ, et al. Diagnosis of Hypersensitivity Pneumonitis in Adults. An Official ATS/JRS/ALAT Clinical Practice Guideline. Am J Respir Crit Care Med 2020;202:e36-e69. https://doi.org/10.1164/rccm.202005-2032ST

6 Rossi G, Cavazza A. Critical reappraisal of underlying histological patterns in patients with suspected idiopathic pulmonary fibrosis. Curr Opin Pulm Med 2019;25:434-441. https://doi.org/10.1097/MCP.0000000000000595

7 Guillotin D, Taylor AR, Platé M, et al. Transcriptome analysis of IPF fibroblastic foci identifies key pathways involved in fibrogenesis. Thorax 2021;76:73-82. https://doi.org/10.1136/thoraxjnl-2020-214902

8 Vukmirovic M, Kaminski N. Impact of transcriptomics on our understanding of pulmonary fibrosis. Front Med 2018;5:87. Doi.10.3389/FMED2018.00087

9 Herrera JA, Dingle L, Montero MA, et al. The UIP/IPF fibroblastic focus is a collagen biosynthesis factory embedded in a distinct extracellular matrix JCI Insight 2022;7:e156115. https://doi.org/10.1172/jci.insight.156115

10 Kamp JC, Neubert L, Stark H, et al. Comparative Analysis of gene expression in fibroblastic foci in patients with idiopathic pulmonary fibrosis and pulmonary sarcoidosis. Cells 2022;11:664. https://doi.org/10.3390/cells11040664

11 Calabrese F, Lunardi F, Tauro V, et al. RNA Sequencing of epithelial cell/fibroblastic foci sandwich in idiopathic pulmonary fibrosis: new insights on the signaling pathway. Int J Mol Sci 2022;23:3323. https://doi.org/10.3390/ijms23063323

12 Jolly MK, Ward C, Eapen MS, et al. Epithelial mesenchymal transition (EMT), a spectrum of states: role in lung development, homeostasis and disease. Dev Dyn 2018;247:346-358 https://doi.org/10.1002/dvdy.24541

13 Chilosi M, Caliò A, Rossi A, et al. Epithelial to mesenchymal transition-related proteins ZEB1, β-catenin, and β-tubulin-III in idiopathic pulmonary fibrosis. Mod Pathol 2017;30:26-3. https://doi.org/10.1038/modpathol.2016.147

14 Yamaguchi M, Hirai S, Tanaka Y, et al. Fibroblastic foci, covered with alveolar epithelia exhibiting epithelial-mesenchymal transition, destroy alveolar septa by disrupting blood flow in idiopathic pulmonary fibrosis. Lab Invest 2017;97:232-242. https://doi.org/10.1038/labinvest.2016.135

15 Marchand-Adam S, Fabre A, Mailleux AA, et al**.** Defect of pro-hepatocyte growth factor activation by fibroblasts in idiopathic pulmonary fibrosis. Am J Respir Crit Care Med 2006;174:58-66. https://doi.org/10.1164/rccm.200507-1074OC

16 Chakraborty S, Chopra P, Hak A, et al. Hepatocyte growth factor is an attractive target for the treatment of pulmonary fibrosis. Hepatocyte growth factor (HGF), a pleiotropic growth factor, plays an important role in lung development, inflammation, repair, and regeneration. Expert Opin Investig Drugs 2013;22:499-515. https://doi.org/10.1517/13543784.2013.778972

17 Heydt C, Ihle MA, Merkelbach-Bruse S. Overview of molecular detection technologies for MET in lung cancer. Cancers 2023;15:2932. https://doi.org/10.3390/cancers15112932

18 Stella GM, Gentile A, Baderacchi A, et al. Ockham's razor for the MET-driven invasive growth linking idiopathic pulmonary fibrosis and cancer. J Transl Med 2016;14:256. https://doi.org/10.1186/s12967-016-1008-4

19 Vukmirovic M, Herazo-Maya JD, Blackmon J, et al. Identification and validation of differentially expressed transcripts by RNA-sequencing of formalin-fixed, paraffin-embedded (FFPE) lung tissue from patients with Idiopathic Pulmonary Fibrosis. BMC Pulm Med 2017;17:15. https://doi.org/10.1186/s12890-016-0356-4

20 Hirsch FR, Bunn Jr PA, Herbst RS. "Companion diagnostics": has their time come and gone? Clin Cancer Res 2014;20:4422-4424. https://doi.org/10.1158/1078-0432.CCR-14-0932

21 Ding C, Qiu Y, Zhang J, et al. Clinicopathological characteristics of Non- Small Cell Lung Cancer (NSCLC) patients with c-MET exon 14 skipping mutation, MET overexpression and amplification. BMC Pulm Med 2023;23:240 https://doi.org/10.1186/s12890-023-02482-9

22 Rossi G, Cavazza A, Marchioni A, et al. Role of chemotherapy and the receptor tyrosine kinases KIT, PDGFRalpha, PDGFR-beta, and Met in large-cell neuroendocrine carcinoma of the lung. J Clin Oncol 2005;23:8774-8785. https://doi.org/10.1200/JCO.2005.02.8233

23 Sontake V, Gajjala pr, Kasam RK, et al. New therapeutics based on emerging concepts in pulmonary fibrosis. Expert Opin Ther Targets 2019;23:69-81. doi.10.1080/14728222.2019.1552262

24 Camidge RD, Morgensztern D, Heist RS, et al. Phase I study of 2- or 3 week dosing of telisotuzumab vedotin, an antibody-drug conjugate targeting c-met, monotherapy in patients with advanced non-small cell lung carcinoma. Clin Cancer Res 2021;27:5781-5792 https://doi.org/10.1158/1078-0432.CCR-21-0765

25 Cooper WA, Mahar A, Myers JL, et al. Cryobiopsy for identification of usual interstitial pneumonia and other interstitial lung disease features. Further Lessons from COLDICE, a Prospective Multicenter Clinical Trial. Am J Respir Crit Care Med 2021;203:1306-1313. https://doi.org/10.1164/rccm.202009-3688OC